

**Leiomyosarcoma involving the inferior vena cava in an  
elderly patient with reference to its operative modalities:  
a case report**

**Hiroshi Ushida<sup>1</sup>, Ryosuke Murai<sup>1</sup>, Mitsuhiro Narita<sup>1</sup>,  
Fumiyoshi Kojima<sup>2</sup> and Yusaku Okada<sup>1</sup>**

**1) Department of Urology,**

**2) Department of Clinical Laboratory Medicine,**

**Shiga University of Medical Science, Shiga, Japan.**

**Abstract**

We report a case of primary pararenal leiomyosarcoma involving the inferior vena cava (IVC) in a 78-year-old woman with exertional dyspnea. In the present case, we performed the tumor resection with transient transection and primary repair of the IVC in order to avoid invasive surgery. Although the usual treatment for younger patients is complete tumor resection with wide margins (IVC and adjacent organs) to minimize relapse, this may be too invasive for aged patients. In this report, we discuss the importance of minimizing the risk of complications following treatments in aged patients.

**Key words:** Leiomyosarcoma, inferior vena cava, elderly patient

To whom correspondence should be addressed at: Hiroshi Ushida MD

Department of Urology, Shiga University of Medical Science, Otsu, Shiga, 520- 2192, Japan.

Tel: +81-77-548-2273; Fax: +81-77-548-2400;

Email: [ushida@belle.shiga-med.ac.jp](mailto:ushida@belle.shiga-med.ac.jp)

## **Introduction**

Primary leiomyosarcoma involving the inferior vena cava (IVC) is a rare lesion with less than 300 cases reported. Due in part to the rarity of leiomyosarcoma of the IVC, the treatment regimen for elderly patients has not clearly established yet. In general, the usual treatment scheme for younger patients includes complete tumor resection with wide margins to minimize relapse. However, it may be too invasive for aged patients. Thus, the current report will focus on surgical management of the IVC to clarify this issue. Here we describe the way of management in a case of primary pararenal leiomyosarcoma involving the IVC in an elderly patient who was treated with transient transection and primary repair of the IVC in order to avoid invasive surgery. In this case, we describe our trial to transient transection of tumor bearing IVC segments for its reuse for vascular reconstruction.

## Case report

A 78-year-old woman with exertional dyspnea visited local hospital where helical computed tomography (CT) of the abdomen showed an  $8 \times 7$  cm heterogeneous mass in contact with the medial side of the right kidney and the posterior side of the IVC (Fig. 1-a). Magnetic resonance imaging (MRI) was carried out in order to evaluate the disease extension to the adjacent major vessels more precisely for the decision of the surgical approach. MRI showed blood flow impairment of the middle and lower segments of the IVC, which extended to the right renal vein. However, there was no thrombosis in these segments (Fig. 1-b).

In this condition, an *en-bloc* resection including the middle and lower segments of the IVC is usual indication. However, this type of surgery would be too invasive for an elderly patient and would carry a high risk for many complications after the treatment. Thus, we chose a less invasive surgical approach that would preserve the IVC. We transected the IVC at the infrarenal portion (Fig. 2-a, b) in order to extirpate the tumor in the free space. The tumor widely adhered to the IVC and right renal vein grossly, but the tumor was relatively easily teased off from the transected IVC. Following this procedure, the resected segment of the IVC was reused for the repair of the IVC. The operative time and amount of bleeding were 6 hours 31 minutes and 2560ml,

respectively. The clamped time of the IVC was 57 minutes. The resected tumor was  $9.3 \times 8.4 \times 6.5$  cm in diameter and weighed 270 grams. Macrographic sections of the specimen appeared homogeneous without hemorrhage or necrosis. Her postoperative convalescence was uneventful without any complications. In particular, the patient did not require long-term anticoagulant treatment since she underwent primary repair instead of prosthetic graft replacement of the IVC.

The pathologic analyses showed that the tumor tissues comprised fascicles of eosinophilic fusiform cells with elongated nuclei with blunt ends. Sizes of the tumor cell nuclei vary mildly (Fig. 3 H.E.), and there were two mitoses per 10 high-power field (Inset). Immunohistochemical analyses revealed that caldesmon and smooth muscle actin (SMA) were positive, however s-100 protein was negative (Fig. 3). These findings were consistent with retroperitoneal leiomyosarcoma. The surgical margins were free of tumor. Although local recurrence occurred 12 months after the initial treatment, the patient is alive with disease 42 months postoperatively.

## **Discussion**

Leiomyosarcoma involving the IVC arise from the smooth muscle cells of the vessel wall, either from IVC itself or its branches. Due to its rarity, optimal management and long-term outcomes are not yet well described. Aggressive surgical management should be attempted for complete excision whenever possible. However, leiomyosarcoma is reported to have a poor prognosis. The overall survival of patients with tumors in all segments of the IVC is 49.4% in 5 years and 29.5% in 10 years, despite complete resection of the tumors with wide free margins<sup>1</sup>. Local recurrence occurred in 33% of the patients, and distant recurrence occurred in 48% of the patients<sup>2</sup>. After aggressive surgical resection, the IVC could be managed using primary repair, ligation, or prosthetic graft. Each procedure has different merits and demerits. For patients of advanced age, the postoperative quality of life (QOL) is especially important since they carry a higher risk for major complications following the invasive surgery which may be lethal<sup>1</sup>. When we choose operative procedures, the cases should be assessed individually to determine the best strategy to reconstruct the IVC for a better prognostic outcome in young patients and to lower the risk of complications in elderly patients.

In fact, there is considerable controversy about the type of caval reconstruction to perform as a treatment for leiomyosarcoma with reference to the patient's age, tumor

location and size, and involvement of adjacent organs. Several authors recommend prosthetic replacement, but others often perform cavoplasty or ligation of the IVC<sup>3-6</sup>.

The type of IVC resection should be tailored individually depending on the topographic tumor expansion. Circumferential IVC resection with graft replacement in particular requires long-term anticoagulant treatment for preventing thrombus formation. If good patency of the graft could not be maintained at the renal vein portion of the IVC, renal failure and leg edema would be induced<sup>1</sup>. In our case, the elderly patient did not require long-term anticoagulant treatment due to the transient transection of the IVC at the infrarenal portion and primary repair instead of prosthetic graft replacement of the IVC.

Our report shows that it is important to minimize the risk of complications following treatments for leiomyosarcoma of the IVC in aged patients.

## Figure legend

Figure 1-a :

The contrast enhanced CT of the abdomen showed an 8 × 7 cm heterogeneous mass which compressed the IVC toward to the anterior side.

Figure 1-b :

MRI did not show the disease extension to the adjacent major vessels and the intramural space of the IVC.

Figure 2-a : Intraoperative views

The IVC was compressed anteriorly. Dissection of the tumor from the IVC was deemed difficult, thus transient transection of the IVC was performed to remove the tumor.

Figure 2-b : Schematic presentation of the tumor resection.

Figure 3 : Histopathological findings (magnification of all pictures, ×100)

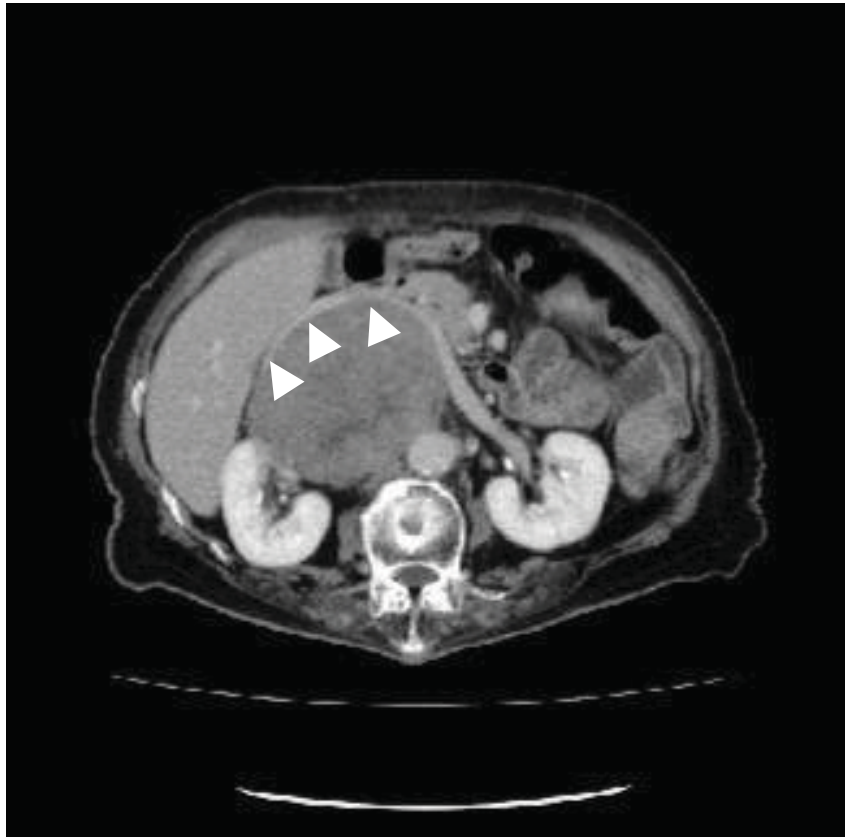
The tumor tissues showed eosinophilic fusiform cells forming fascicles. There were a few mitoses (Inset). Immunohistochemical stains for caldesmon and smooth muscle actin (SMA) were positive, however s-100 protein was negative.



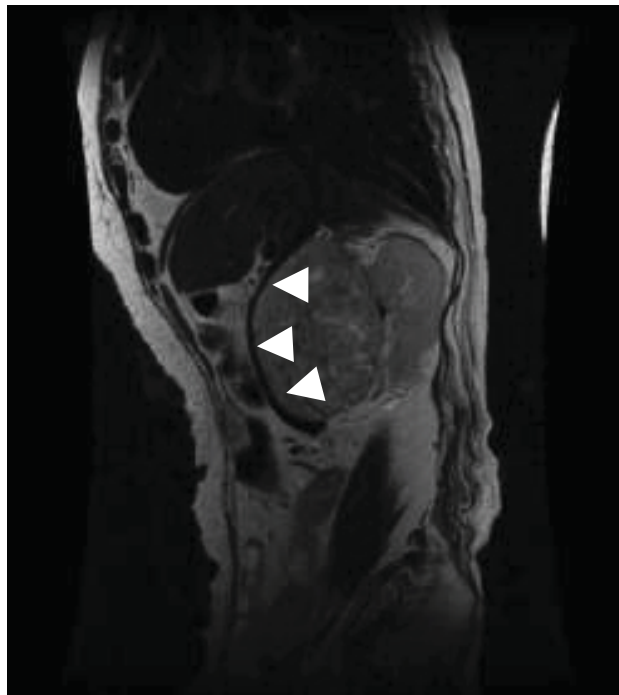## References

- 1, Mingoli A, Cavallaro A, Sapienza P, Di Marzo L, Feldhaus RJ, Cavallari N. International registry of inferior vena cava leiomyosarcoma: analysis of a world series on 218 patients. *Anticancer Res.* Sep-Oct;16 (5B):3201-5, 1996.
- 2, Hollenbeck ST, Grobmyer SR, Kent KC, Brennan MF. Surgical treatment and outcomes of patients with primary inferior vena cava leiomyosarcoma. *J Am Coll Surg.* Oct;197 (4):575-9, 2003.
- 3, Alexander A, Rehders A, Raffel A, Poremba C, Knoefel WT, Eisenberger CF. Leiomyosarcoma of the inferior vena cava: radical surgery and vascular reconstruction. *World J Surg Oncol.* Jun 26; 7:56, 2009.
- 4, Cho SW, Marsh JW, Geller DA, Holtzman M, Zeh H 3rd, Bartlett DL, Gamblin TC. Surgical management of leiomyosarcoma of the inferior vena cava. *J Gastrointest Surg.* Dec;12(12):2141-8, 2008.
- 5, Ito H, Hornick JL, Bertagnolli MM, George S, Morgan JA, Baldini EH, Wagner AJ, Demetri GD, Raut CP. Leiomyosarcoma of the inferior vena cava: survival after aggressive management. *Ann Surg Oncol.* Dec;14(12):3534-41, 2007.
- 6, Kieffer E, Alaoui M, Piette JC, Cacoub P, Chiche L. Leiomyosarcoma of the inferior vena cava: experience in 22 cases. *Ann Surg.* Aug;244(2):289-95, 2006.

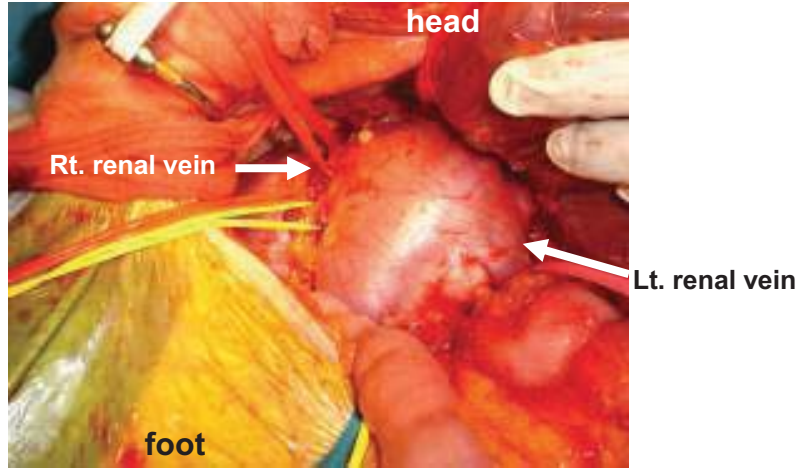
**Fig.1-a**



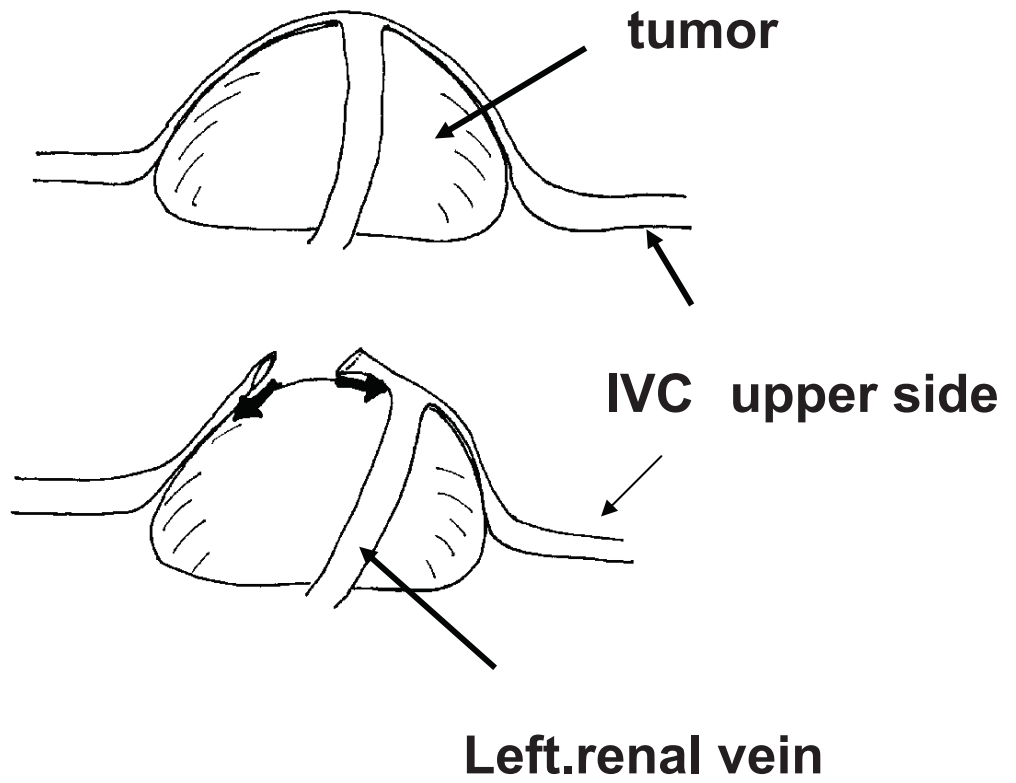
**Fig.1-b**



**Fig.2-a**



**Fig.2-b**



**Fig.3**

